

SUPREME COURT OF THE STATE OF NEW YORK
COUNTY OF NEW YORK: PART 42

THE PEOPLE OF THE STATE OF NEW YORK

-against-

CLARENCE DEAN,

Defendant.

REPLY TO POST-
FRYE HEARING
BRIEF REGARDING
FORENSIC
ODONTOLOGY

Ind. No. 4555/2007

Cyrus R. Vance, Jr.
District Attorney
New York County

By: 
Melissa Mourges
Assistant District Attorney
Of Counsel
212 335 4209

Preliminary Statement

Clarence Dean was indicted and charged with Murder in the Second Degree in 2007.

In October 2008 the prosecution disclosed a report prepared by Dr. Lawrence Dobrin indicating a link between Clarence Dean and a bitemark found on the breast of the murder victim.

This brief is submitted in reply to the Frye motion and brief submitted by counsel for Clarence Dean and to the filed by the Innocence Project as amicus in this case. This reply is based upon the testimony and evidence adduced at the Frye hearing conducted in this matter as well as upon attendance at meetings of the Forensic Odontology section and other sections of the American Academy of Forensic Science, journal articles, transcripts of other proceedings, and conversations with Dr. Thomas J. David, Dr. Robert Shapiro, and Brad Gessner, prosecutor in Summit County, Ohio.

Introduction

This Frye hearing is an attempt by the defense to upend over thirty years of judicial acceptance of bitemark testimony in New York and to urge the Court to ban forensic odontology testimony, a step not taken in any jurisdiction in the United States. The defense claims that approximately a dozen exoneration cases in which bitemark comparisons provided some of the evidence against the accused, coupled with recommendations in the 2009 National Academy of Science report “Strengthening Forensic Science in the United States: A Path Forward (NAS Report)” means that evidence from bitemark analyses and comparisons are no longer accepted as reliable and must be precluded from courtrooms. The defense is wrong.

Forensic Odontology: Practitioners and Procedures

Any discussion of bitemark evidence must start with a clear understanding of the protocols and procedures involved in forensic odontology and the experience and skills necessary to collect bitemark evidence, analyze bitemarks and compare those marks to suspected biters. It is also important to understand the central role played by forensic odontology’s accrediting body, the American Board of Forensic Odontology (ABFO) in setting and maintaining standards for the conscientious practice of forensic odontology.

Forensic dentists undergo standard medical dental training during which they take the same courses as medical students in pharmacology, physiology, histology and anatomy of the oral and facial structures. Then, forensic dentists undergo additional training, and candidates for certification by the American Board of Forensic Odontology (ABFO) have a daunting list of requirements to meet before they are eligible for Diplomate status. Candidates must take a recognized forensic odontology course of study, attend a minimum of five autopsies, perform a minimum of 35 forensic dental cases, including a minimum of seven bitemark cases, five age estimations and at least 20

victim identifications (10 in which they must personally take the postmortem radiographs and five in which they must personally perform resection or surgical exposure), testify or give depositions at least twice, pass an examination, and fulfill a number of other forensic odontological tasks including research, publication and affiliation with a medico-legal organization such as a medical examiner or coroner's office. Diplomates face recertification every five years.

Dr. David Senn, who testified on behalf of the prosecution, has been a dentist for over 40 years. He was a dental officer in the Army, had a general dentistry practice for 20 years, and has served on the forensic odontology staff of the Bexar County Medical Examiner's Office in San Antonio, Texas for 20 years, nine of them as Chief. He is also a Clinical Assistant Professor at the University of Texas Health Science Center, where he heads the two-year post-doctoral program in forensic odontology. This program, the only one of its kind in the United States, attracts dentists from around the world. He is board certified by, and past-president of, the American Board of Forensic Odontology. (As described below, the ABFO serves to establish standards for and to certify qualified specialists in forensic odontology.) Dr. Senn is co-chair of the forensic odontology subcommittee of the FBI's Scientific Working Group for Disaster Victim Identification (SWGDIV). He is Secretary of the Forensic Specialties Accreditation Board (FSAB). As a member of the federal Disaster Mortuary Operational Response Team (DMORT), Dr. Senn spent 52 days working with the Office of the Chief Medical Examiner in the wake of the September 11th attacks helping to identify the dead. He also responded as a DMORT team member to recover remains of astronauts after the Shuttle Columbia crash and after hurricanes Katrina and Rita. All told, he has participated in the identifications of over 500 people.

As a forensic odontologist, Dr. Senn responds to hospitals and morgues to conduct analyses of patterned injuries suspected to be bite marks in child abuse, elder abuse and intimate partner

abuse cases, murders, sexual assaults, and barroom brawls. He performs age estimations for immigration and other authorities. He also consults in civil cases involving personal injury, standard of care and state board actions against other dentists. He has examined in excess of 300 patterned injuries suspected to be bitemarks.

He has testified many times as an expert in forensic odontology for both the prosecution and the defense; notably, he was retained (or worked pro bono) for the Innocence Project in three separate cases.

Dr Senn was the co-editor of the two most recent forensic odontology textbooks, the Manual of Forensic Odontology, 5th Edition and Forensic Dentistry, 2nd Edition. He contributed chapters to other forensic dentistry textbooks, including Dental Clinics of North America, Bite Mark Evidence, 2nd Edition, the Manual of Forensic Odontology, fourth and fifth editions and Forensic Dentistry, 2nd Edition. He has also written many articles for peer-reviewed journals, including the Journal of Forensic Sciences and the Journal of Pediatric Dentistry, and he testified before the National Academy of Sciences during their review of forensic science.

Victim Identifications

Making victim identifications from features of the teeth and jaws requires the same tools and skills related to bitemark analysis and comparison. When there are 32 teeth and the mouth is intact, forensic dentists find it a relatively simple matter to identify individuals through dental records. However, forensic dentists often work successfully with much less information. Working with extremely compromised samples from disaster victims, Dr. Senn has made identifications from very small bone or tooth fragments. He demonstrated making a positive identification from x-rays that showed parts of only three teeth, and explained how one individual was identified multiple times using 17 different jaw and tooth fragments, all belonging to one victim at the World Trade Center.

Bitemark Analysis and Comparison

Dr. Senn describes bite marks as “patterned injuries.” Dr. Senn explained the procedures involved in bitemark analysis and comparison, from evidence collection through analysis and comparison to drawing conclusions and writing a report. His testimony was accompanied by over 100 color slides, which powerfully illustrated his points using photographs of actual cases.

Typically, police, emergency room physicians or medical examiners call a forensic dentist to examine a suspected bitemark. (In fact, while he was on the witness stand testifying in this case, Dr. Senn received a cellphone photo of a suspected bite from a doctor in a Texas pediatric emergency room, requesting advice.) The forensic dentist’s first step is to ascertain that someone has swabbed the injury for salivary residue in the hope of recovering the biter’s DNA. If forensic dentists swab the area themselves, they use a two-swab method. They wet the first swab with sterile saline and scrub it over the injury. This maximizes sample recovery by leaving moisture that forensic dentists then collect with a second dry swab. Following swabbing, the forensic dentist or a forensic photographer will take progressively closer orientation photos to document the injured area of the victim’s body, whether on a hospital bed or a gurney in a morgue.

After that, the forensic dentist will take additional photographs to document and detail the features of the patterned injury. Some photos should include a measuring device called the ABFO #2 scale, to insure that comparisons can be made between images that are the same size and can then be reliably compared.

Forensic dentists may use special photographic techniques, including fluorescent photography, color and gray scale photography, ultraviolet photography (for surface detail, especially of abrasions), and infrared photography, which allows light to penetrate beneath the skin’s surface to

examine subcutaneous details. All of these techniques are part of the documentation and preservation of the injury as evidence in a given case.

Forensic dentists may take impressions of three-dimensional features, including tooth impressions and drag marks on the skin, to capture those features as well as the curvature of the skin. They take these impressions using the same vinylpolysiloxane (VPS) material dentists regularly use to make bridges and crowns.

Finally, in cases where the victim is dead, forensic dentists may remove and retain the bitten tissue. To do this, they place a custom-made ring around the bitemark, glue and then suture it to the skin to preserve its orientation and anatomical shape and then surgically remove the entire area from the body. By harvesting the tissue, forensic dentists can examine damage done beneath the skin's surface. Once skin is harvested, forensic dentists can perform a process called transillumination. They place light behind the harvested tissue to expose injury patterns not visible from the surface. Even in cases where the tissue is not removed, forensic dentists can expose and see damage by making an incision through the injury.

Is it a Bitemark?

After collecting evidence, the vital first step forensic dentists take is to determine whether an injury is, in fact, a bitemark. Using class characteristics of bitemarks such as oval, elliptical or curved interrupted linear patterns including visible individual marks made by individual teeth, distinguishing characteristics may enable forensic dentists to determine what types of teeth may have made them. In addition, central contusions or ecchymosis may appear as redness or bruising in the center of the mark. An incision into that contusion may show bleeding into subcutaneous tissue and fat caused by crushing or blunt force trauma by the teeth causing capillaries to burst and leak blood into surrounding tissues.

The ABFO has three categories to indicate levels of confidence about whether a patterned injury is a bitemark:

1) It is a bitemark, meaning teeth created the pattern and other possibilities were considered and excluded; 2) It is suggestive of a bitemark, meaning the pattern is suggestive of a bitemark but there is insufficient evidence to reach a definitive conclusion at this time; and 3) It is not a bitemark; teeth did not create this pattern.

Of course, if the forensic dentist lacks sufficient evidence to make a determination, he would render no judgment. Dr. Senn estimates that, of the 50 suspected bitemarks he evaluates a year, up to 85% of them are not suitable for analysis.

Severity of the Bite

It might seem that the more severe a bitemark, the more evidence it will yield, but that is not so. The least and the most severe bites may give the least information. British forensic odontologist Dr. Ian Pretty developed a severity scale, indicating that bitemarks at either end, from mild bruising on the one hand to complete avulsion or traumatic tearing away of tissue on the other, have low forensic significance. This is because either type of injury could have been caused by something other than teeth. However, those injuries in the middle of the severity scale, with very obvious markings from individual teeth including bruising and laceration, drag marks and compression artifacts are more likely to be assessed as bitemarks, and are of higher forensic significance.

Increasing severity

1) Very mild bruising, no individual tooth marks present, diffuse arches visible, may be caused by something other than teeth – low forensic significance

2) Obvious bruising with individual, discrete areas associated with teeth, skin remains intact, moderate forensic significance

3) Very obvious bruising with small lacerations associated with teeth on the most severe aspects of the injury, likely to be assessed as definite bite mark, high significance

4) Numerous areas of laceration, with some bruising, some areas of the wound may be incised. Unlikely to be confused with any other injury mechanism and a high forensic significance.

5) Partial avulsion of tissue, some lacerations present indicating teeth as the probable cause of the injury. Moderate forensic significance.

6) Complete avulsion of tissue, possibly some scalloping of the injury margins suggested that teeth may have been responsible for the injury. May not be an obvious bite injury – low forensic significance

High
forensic
significance

Creating a Biter Profile

A forensic dentist should be able to tell from a bitemark that has evidentiary value not only which marks were made by the upper and lower teeth, but which individual teeth made individual marks. Once he has collected photos of the bitemark, the forensic dentist may be able to create a "biter profile." The best practice is that the forensic dentist does this before he looks at any suspect's teeth, so nothing about the suspect's dentition introduces bias in the creation of the profile. Sometimes a forensic dentist will use computer programs to enhance the images and to make the comparison process simpler and more consistent between suspects. Dr. Senn described how he would use a computer drawing tool to mark each of the features in the bitemark he could see, using lines, outlines and dotted lines. He described the use of the universal numbering system to identify the specific tooth he suspected made particular marks. He may also use the features seen in the patterned injury to predict possible dental features of the person who made the mark.

Collecting Suspect Exemplars

The forensic dentist who examined and recorded the information from the patterned injury or bitemark should not collect evidence from the suspect(s); the best practice is to use another dentist for this task. That dentist should take photos of the suspect sufficient to identify him by face. Then, the forensic dentist should take intraoral photos to show details of the teeth. In order to show the relative heights and lengths of the teeth, the forensic dentist should take pictures from multiple angles including directly from the front. He should focus additional photos, including some taken using a mirror if needed, directly toward the biting surfaces of the teeth. The dentist should have the suspect bite down into some appropriate material such as dental wax that records prints of the suspect's teeth. In addition, the dentist should make impressions of the suspect's upper and

lower teeth, using appropriate dental materials, and create dental models from those impressions. If this has not already been done, the forensic dentist should also collect DNA samples from the suspect using accepted cheek swabbing techniques. Dr. Senn uses, teaches and recommends that the forensic dentist employ yet another best practice if there is only one suspected biter and ask independent associates to gather models and create a “dental line-up” ensuring that the examining forensic dentist does not know which model belongs to the suspect.

Forensic dentists should use a properly calibrated flatbed scanner along with an ABFO scale to scan the models and a properly placed ABFO#2 scale. The resulting images can be used to create exemplars, including “hollow volume overlays” which captures the outline of each of the suspected biter’s teeth. Comparisons can be made using both the scanned images and the actual models.

The Comparison Process

Dr. Senn described placing the hollow volume overlays of each suspect’s upper and lower dentition on the same screen with same-scaled images of the bitemarks. He compared them by moving each overlay over the bitemarks, one at a time. Both the image of the bitemark and the hollow volume overlay contain a ruler to insure they are scaled the same. If Dr. Senn saw drag marks in the bitemark, he could move the overlay along the path of the drag marks to see whether they are consistent. Dr. Senn described the features he would compare, including arch shape and width, and the size, width, alignment and rotation of specific teeth.

Conclusions

Based upon ABFO Bitemark Terminology guidelines, the forensic dentist may come to any of the following conclusions to relate a suspected biter to a bitemark: The Biter, The Probable Biter, Not Excluded as the Biter, Excluded as the Biter, or Inconclusive. The guidelines specify that these

links are stated to “reasonable medical, dental or scientific certainty”. This means that the linkage term “The Biter” does not indicate absolute certainty but only reasonable certainty. The ABFO standards for bitemark terminology include the following caveat: Terms assuring unconditional identification of a perpetrator, or without doubt, are not sanctioned as a final conclusion.

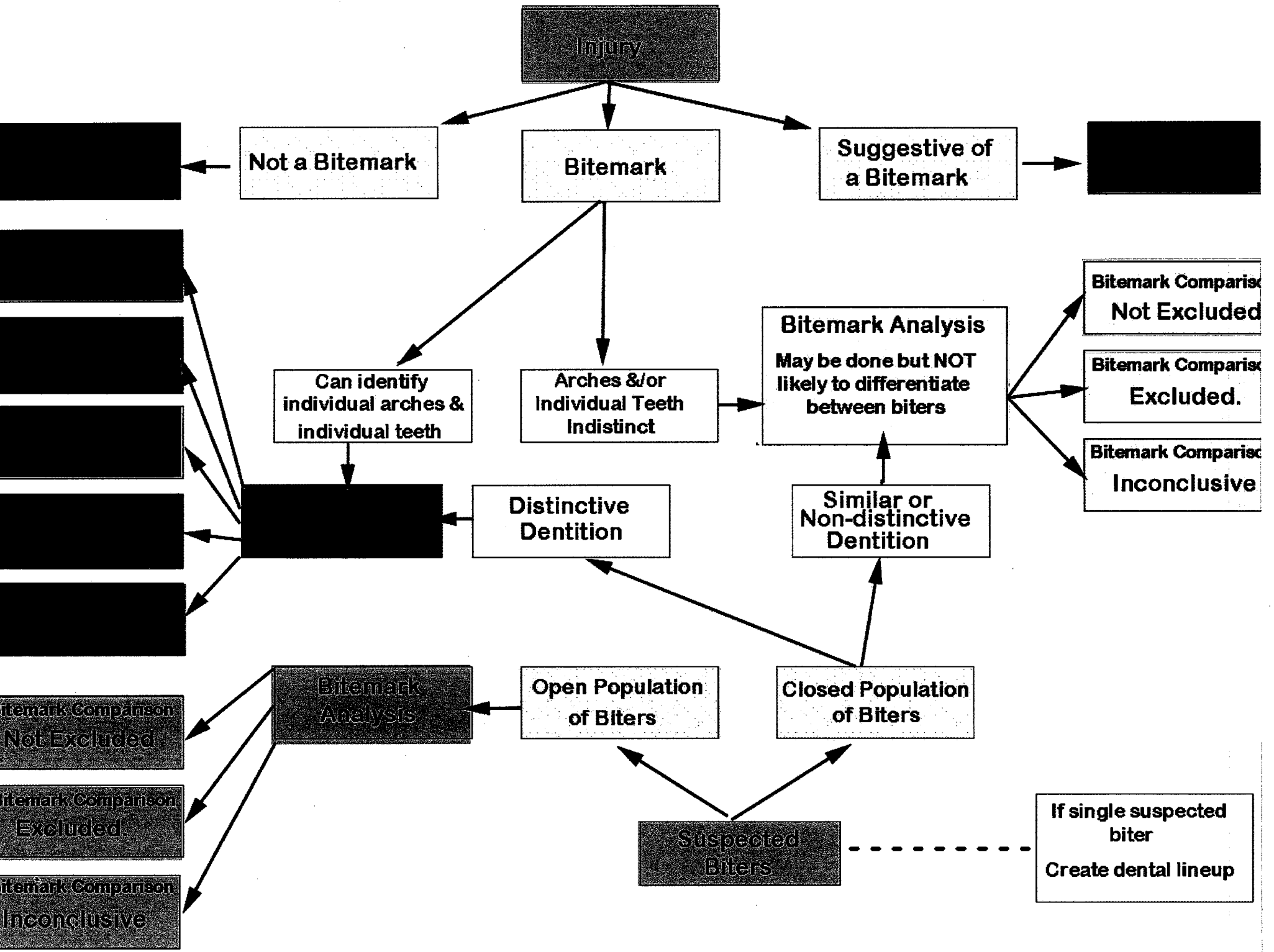
Dr. Senn also described the difference between a “closed” population with a limited number of potential suspects, and an “open” population where anyone could be a suspect. Dr. Senn said that it would be difficult to link a single person to a bitemark as “The Biter” in an open population, based on pattern (bitemark) evidence alone, absent other corroborative evidence such as DNA or a witness who observed the bite. He noted however, that a majority of his forensic odontology cases involve abused children in a closed population, where a limited number of people have access to the child. In those cases, with a high level of distinctive bitemark and a high level of distinctive dentition in a suspect, Dr. Senn said he would make any ABFO linkage conclusion supported by the evidence.

The ABFO

The American Board of Forensic Odontology (ABFO) was established under the auspices of the National Institute of Justice and the American Academy of Forensic Sciences in 1976. The mission of the ABFO is to establish, enhance, and revise as necessary standards of qualifications for those who practice forensic odontology and to certify as qualified specialists those voluntary applicants who comply with and satisfy the requirements of the Board. The ABFO is comprised of individuals who are national and internationally recognized experts, and is accredited by the Forensic Specialties Accreditation Board as a forensic specialty offering board certification to qualified dentists. The ABFO has a meeting each February in conjunction with the annual meeting of the American Academy of Forensic Sciences. At this meeting, the ABFO offers lectures and workshops

on dental identification, dental age estimation, bitemark evidence management and expert witness testimony. The ABFO's Examination and Certification Committee conducts Diplomate certification examinations for new applicants and periodic recertification examinations for current members.

The ABFO publishes a 187- page Diplomates Reference Manual that includes the ABFO Bitemark Methodology Guidelines. These guidelines detail methods to collect and preserve bitemark evidence, collect evidence from suspected biters, describe bitemarks, compare exemplars to bitemarks, and the use of specific methods and tools to enhance bitemarks for analysis. The guidelines also define terms indicating degrees of confidence that an injury is a bitemark and terms relating a suspected biter to a bitemark. The Guidelines describe the bitemark case review policy and set out bitemark report writing formats. An important Guideline revision was added in February 2013 when the ABFO voted to include a bitemark flow chart or decision tree, included below. Properly used, the decision tree will guide forensic odontologists' investigatory paths leading to proper conclusions based on the quality of the bitemark and the teeth of the suspected biters. This new guideline offers specific recommendations for forming degrees of linkage conclusions based on the quality of both injury features and suspected biter dentitions. (The report in the instant case, initially written in 2008, will be reviewed to see whether changes consistent with the new guidelines are required.)



Definition of Terms

The Innocence Project attempts to define terms with the following footnote, on page 9 of their amicus brief: “Hereinafter, the terms “bite mark evidence” or “bite mark analysis” are used to describe “positive bite mark evidence” or testimony from a forensic dentist that a bite mark is either consistent with the dentition of an alleged perpetrator, or that the bite mark was in fact made by an alleged perpetrator. This should be distinguished from evidence that establishes that a given individual was *not* the person who produced the bite mark in question.”

This bit of sophistry is a transparent attempt to live in the best of all possible defense worlds—one that precludes forensic odontology testimony when it inculpates but allows the defense to embrace forensic odontology when it exonerates. The definition proposed by the Innocence Project is factually incorrect, and it cannot stand.

Dr. Thomas J. David, immediate past president of the ABFO, a DMORT team member and veteran forensic dentist with 35 years’ experience who consults frequently with medical examiners, prosecutors and defense attorneys, explains what is wrong with the proposed word play. He says the terms “bitemark evidence” and “bitemark analysis” are not interchangeable and should not be used to describe only so-called “positive” bitemark evidence or testimony. Bitemark evidence is properly described as tangible evidence of a patterned injury, most often in the form of photographs, but can include exemplars or impressions. Collecting bitemark evidence is the first step in a multi-step process. After obtaining evidence of a patterned injury, the forensic dentist determines whether the injury is a human bitemark. If the answer is yes, the next question is whether there is sufficient evidentiary value in the bitemark for comparison to potential biters. If there is insufficient evidentiary value, no comparison can be done. If sufficient evidentiary value exists, comparisons can be made. Thus, the entire process has three phases:1) evidence collection;

2)analysis of evidence; and 3)comparison of evidence. All forensic investigative processes must have the first two steps; a much smaller number proceed to step three. Therefore, a description of bitemark evidence or bitemark analysis as positive evidence or testimony that links a suspected biter is, in fact, wrong. Any opinion concerning linkage of a potential biter to a bitemark is a bitemark comparison, not an analysis. However, once a bitemark comparison is undertaken, then all of the possible linkage terms must be considered together. They would include not only the conclusions listed by the Innocence Project, “consistent” (not excluded) and “bitemark was in fact made by an alleged perpetrator”(biter) but also the other possible linkage opinions—excluded, inconsistent and insufficient evidence. All five of these linkage terms are part of the same process if and when a comparison is undertaken. It is impossible to separate exclusion from consideration along with the other terms; they all require the same thought process. The same analysis is done to come to an exclusion as to come to an inclusion, the same features used to exclude can be used to include, and in some circumstances excluding all but one can lead to inclusion. Dr. David’s conclusions mirror Dr. Senn’s testimony, as well as the ABFO guidelines, above.

The NAS Report

The defense cites the 2009 National Academy of Science advisory report “Strengthening Forensic Science in the United States: A Path Forward” over a combined 20 times in their briefs to support their claim that forensic odontology is scientifically unsound. Nothing in the NAS report supports that conclusion, and no jurisdiction in the United States has outlawed bitemark testimony in response to the NAS report. First, it is important to look at what the NAS report does *not* do. The report does not claim to be an authoritative treatise on any forensic science. The 286 page report expends less than four pages on a discussion of forensic odontology (NAS report at 173-177.) The brief treatment of forensic odontology is not surprising, given that “the NAS committee decided

early in its work that it would not be feasible to develop a detailed evaluation of each forensic discipline in terms of scientific underpinning, level of development and ability to provide evidence to address the major types of questions raised in criminal and civil litigation.” Nor was the report authored by experts in each forensic field; while the committee had numerous academics and statisticians, no forensic odontologists made the cut. And while the NAS report unquestionably suggests federal regulation of forensic science, the NAS report does not state that forensic odontology as a field should be discredited.

Nowhere does the NAS report urge, as the defense claims, that forensic odontology is based on methodologies not accepted by the relevant scientific communities. To the contrary, the NAS report states that there are well-established guidelines for the collection of evidence, for example, various forms of photography, dental casts, clear overlays, computer enhancement, electron microscopy and swabbing for serology or DNA, that are well-established and non-controversial. While the report notes that bitemarks on the skin will change over time and can be distorted by the elasticity of the skin, the unevenness of the surface bite and swelling and healing, these are features that are well-understood by forensic dentists and their analyses and comparisons take those and many other factors into account. . The NAS report notes with approval the caution the ABFO dictates when setting the standards for reaching conclusions of linkage between a biter and a bitemark, pointing out the ABFO caveat that “Terms assuring unconditional identification of a perpetrator, or without doubt, are not sanctioned as a final conclusion.” The NAS report notes the significance of bitemark analysis and comparison, citing the fact that bitemarks are seen most often in cases of homicide, sexual assault, and child abuse.

Nowhere does the report state or even imply that forensic odontology should be deemed inadmissible under either Frye or Daubert. That point was addressed clearly by a federal judge,

Harry Edwards, who is Chief Justice for the D.C. Circuit and co-chair of the NAS Committee. In his address to Congress on the subject of the NAS report, Justice Edwards said, “The question of whether forensic evidence in a particular case is admissible under applicable law is not co-terminus with the question of whether there are studies confirming the scientific validity and reliability of a forensic science discipline.”

The policy recommendations summarized in the NAS Report are not intended to determine the admissibility of evidence, but to determine the need, if any, to create a federal regulatory agency devoted to the standardization of forensic science

The fairness of the entire NAS inquiry, at least with regards to forensic odontology, has been called into question by Dr. Senn, who personally testified before the NAS Committee. It is fair to say that no one was more aware of the failings of some forensic dentists than Dr. Senn as he prepared to testify before the NAS committee. And nowhere has the adage “no good deed goes unpunished” been more starkly illustrated than by the use to which his testimony has been put. Dr. Senn pointed out in detail how the NAS committee ‘cherry-picked’ journal articles for negative findings while ignoring the positive and cited an article that repeatedly and erroneously called a survey a “proficiency exam” when it was not. He showed how the reports of some biased researchers were log-rolled in a frenzy of circular citations.

Dr. Senn testified at our hearing that the NAS Committee ignored much of what he had to say. “My answers included these things: Forensic odontologists understand the anatomy and the function of teeth and the dynamic mechanics of biting. A competent, skilled odontologist can produce biter profiles from bite patterns that exhibit sufficient information to have evidentiary value. Competent forensic odontologists will conform to the American Board of Forensic Odontology bite mark methodology guidelines for evidence collection, evidence comparison and for

report writing, and for ethics. The state of the art is defined by forensic odontologists who are capable of using all the known evidence collection and comparison modalities and collect the modality that's appropriate for the case in question. And employ blinding techniques to inhibit bias or observer effect and evidence collection, evidence analysis, and even employing dental lineups. And they seek second opinions from independent, blinded, competent forensic odontologists and engage in continuing study and research to improve themselves and forensic odontology and abide by the code of ethics and conduct. None of those items were included or mentioned or even referred to in the report." (Senn transcript p. 118).

Both federal and state courts have interpreted the NAS Report as acknowledging the need for further research and regulation in forensic science, not as an affirmative directive demanding judges "to take the drastic step of excluding long accepted forms of expert evidence." United States v. David Brian Stone, (2012 U.S. Dist. LEXIS 8973 12) (denying defendant's motion to exclude expert testimony regarding latent fingerprint identification on the basis of the NAS Report). Federal courts have gone so far as to say that "while an important contribution to the evaluation of numerous forensic fields, the report does not bind federal courts." United States v. Aman, 748 F. Supp. 2d 531, 536 (E.D. Va. 2010) (finding that expert testimony in fire investigation, fingerprint analysis, gas chromatography/mass spectrometry were founded on the use and application of reliable methodologies in their respective fields and denying defendant's motion to exclude). In Gee v. United States, 54 A.3d 1249 (D.C.2012), the D.C. Court of Appeals ruled the trial court was correct in refusing to find that the NAS report was reliable authority on the issue of friction ridge analysis, and found that no other court had accepted the relevant portions of the report as a learned treatise. In Pettus v. United States, 37 A.3d 2013 (D.C. 2012) the D.C. Court of Appeals discussed the NAS report in the context of handwriting identification. The Court rejected the amicus argument that the NAS Report taken as a whole amounts to a critique and repudiation of the

supposed science underlying all forensic analysis based on pattern-matching, except for DNA. The Court found, “The Report is much more nuanced than that... the goal is not to hold other disciplines to DNA’s high standards,” since “it is unlikely that most other current forensic methods will ever produce evidence as discriminating as DNA.” (Id. at 226). The Court further noted, “Yet in virtually no instance...does the Report imply that evidence of forensic expert identifications should be excluded from judicial proceedings until the particular methodology has been validated.”(Id. at 226).

In 2010, the Kansas Court of Appeals addressed the legitimacy of forensic odontology evidence in light of the recommendations made by the NAS Report. State of Kansas v. Lopez-Martinez 2010 WL 2545626 (Kan. App.) The court held that the NAS Report was not binding authority and should not be treated as such. In New York, the NAS Report has received little if any judicial attention. (See People v Carreira, 27 Misc. 3d 293 (NY City Ct 2010) mentioning the NAS Report in regards to hearsay requirements and forensic analyst lab reports). In New York, no federal or state court has yet to order the suppression of expert testimony in a criminal trial based on the NAS Report’s recommendations.

Forensic Odontology is Not a Lab Science

While acknowledging that Forensic odontology is an “experienced-based” forensic method like many other disciplines, the NAS Report nonetheless complains that there is a lack of empirical and statistical data to support concepts like match rate, error rate, the uniqueness of human dentition, or the ability of human skin to transfer and maintain a pattern. Forensic odontology is not a hard science like DNA analysis, where researchers can sit at a lab bench and perform the same experiments over and over to establish ground truths. Each bite is a unique event. Even consecutive bites inflicted rapidly between the same biter and victim will each be different, as the

victim reacts to pain by moving away as quickly as possible, each moment changing the relative positions of the biter and victim. We cannot inflict extremely violent test bites on large numbers of people for the purpose of research. The difficulty in constructing useful experimental models for bitemark scenarios was starkly illustrated by the problems Dr. Mary Bush was unable to surmount, which are discussed below.

Forensic odontology is an observational science, where the skill and experience of the forensic dentists informs his good judgment in a particular case. In this way forensic odontology is much like forensic pathology. We cannot, for example, investigate the effects of gun shot wounds on human beings by lining people up and shooting them. Nor can we determine the lethal dose of a drug like fentanyl by dosing volunteers and gradually increasing the dosage until we kill them. Instead, we have to wait for gun shot victims or overdose victims to come to the morgue and make our observations. We rely on the training, skill and experience of the forensic pathologist and the forensic odontologist to come to the right conclusions. We can expose deficits in their education and experience and identify ways in which they deviate from best practices and standards through vigorous cross-examination and presentation of experts with different opinions, if those opinions are forensically sound.

Defense Expert Mary Bush

The defense presented Dr. Mary Bush in an effort to disparage the scientific underpinnings of forensic odontology. They refer to Dr. Bush as a forensic odontologist. She is not. While she is a licensed general dentist and a professor of dentistry, Dr. Bush has no experience whatsoever in real world forensic odontology. She has never seen a real bitemark firsthand, never collected evidence in a real world bite mark case, never taken photographs of a real bitemark, never collected a bitemark impression in a victim, never swabbed a real bitemark for DNA evidence, never harvested the skin

of a deceased victim of a real bitemark, never processed evidence in a real world bitemark case, never created Adobe Photoshop enhancements of a bitemark, never collected evidence from a suspected biter, never created an acetate overlay or a hollow volume overlay of a suspected biter's teeth in a real case, never done an analysis and comparison in a real bitemark case, and never written or presented a report on the findings of analysis and comparison in a real world case. She is not a member of the FBI's Scientific Working Group for Disaster Victim Identification, nor is she a member of the federal Disaster Mortuary Operational Response Team. She has not participated in disaster victim identification other than to aid in the chemical analysis of filling materials in three tooth fragments recovered by other people in the aftermath of a Buffalo plane crash. She is not a Diplomate of the American Board of Forensic Odontology, and by her own admission would not meet their rigorous standards for certification.

For these reasons it is perhaps unsurprising that the two experimental models Dr. Bush and her colleagues designed in an attempt to test what they considered to be important aspects of forensic odontology failed to replicate any aspect of violent real world biting situations or to provide useful information about real world victims or real world teeth.

Dr. Bush and her team devised two basic experiments. One purported to be an attempt to determine how reliably teeth leave imprints in skin. It involved the use of dental models mounted in a vice grip and pinched against the skin of a cadaver hard enough to leave indentations of the tooth models in the cadaver skin. The second purported to determine whether human dentition was unique. It involved placing dental models on a flatbed scanner, then performing various statistical calculations regarding the scanned dental models. Dr. Bush described her experiments, which were also documented in articles in the Journal of Forensic Sciences.

The cadaver studies were performed on cadavers taken from morgue coolers and defrosted to “room temperature”. Then, stone dental models mounted in Home Depot vice grips were placed on the cadaver skin and were pinched for a length of time sufficient to create indentations in the skin. Those indentations were photographed quickly because they disappeared in a matter of minutes as the skin rebounded.

Dr. Bush conceded that there were numerous differences between her experimental model and real world victims, real world jaws, real world teeth and real world bitemarks.

Living bodies, of course, behave much differently than cadavers. First of all, living bodies register at approximately 98.6 degrees F. Living skin is a complex organ system, with blood flowing through a vast vascular network, pumped by the human heart, all of which gives the skin resiliency, flexibility and strength. Skin is rich in pain receptors, which cause a living person to react to the pain of biting and to quickly move away from the source of that pain, even if that movement inflicts further injury. When blood vessels are broken, say by being bitten, blood flows into surrounding tissue. And when skin is damaged, the body tries to protect itself by releasing chemicals called prostaglandins and histamines, which cause inflammation. This is the body’s attempt to minimize bleeding and minimize tissue damage. And then, the body starts to heal, sending out cells to repair skin by scarring or regeneration.

Cadavers, on the other hand, have no vital reactions whatsoever; they are dead. Instead of raising the cadaver temperature to 98.6 degrees, the Bush team used them at “room temperature” which she guessed was approximately 70 degrees F. She concedes there was no scientific reason to expect that cadaver skin would behave the same as live skin at any temperature, much less when that cadaver skin is cooled down almost 30 degrees. She did not record the temperature, gender, age, occupation, cause of death, ethnicity, condition, skin type or color of any of the cadavers, except to

note that none of the cadavers were Black, since the indentations they intended to photograph were not visible in photos of Black skin. She could not account for the degree of decomposition that would naturally occur in the cadavers, but agreed that decomposition starts within minutes after death. She conceded that the cadavers did not move, feel pain, bleed, bruise, inflame, heal, or scar.

A real human jaw is far different than the vice grip device used in the experiment. When a human jaw opens it moves in two separate ways. A human jaw hinges and translates so that the joint comes out of the socket so one can open wide enough to take a big bite. In addition, a lower jaw can move from left to right and jut in and out. When teeth in a human jaw are positioned to take a bite of something, they are in what is called protrusive occlusion, where the lower jaw protrudes and the biting edges of the top and bottom teeth come together to more efficiently rip or tear the food.

Dr. Bush concedes that the vice grips, unlike a human jaw, were capable of moving in only one direction, up or down. She also agreed that the teeth were mounted not in a biting position but in centric occlusion, where the top teeth overlap the bottom and the back of the front teeth contact the front of the back teeth, which is different than the position real teeth take during a bite and is more likely to pinch than bite. Additionally, Dr. Bush admitted that in some studies she combined a set of lower teeth from one person with a set of upper teeth from a different person, a configuration that could never occur in real life.

Dr. Bush testified that “slow and steady, even pressure” was kept on her biting mechanism for up to 19 seconds. She conceded that slow, steady and even pressure is far different from what would occur in a real bite and she said that 19 seconds was an “unreasonably long” biting time, far in excess of what would happen in real life. She conceded that they were unable to break the skin

with their experimental vice grip pinch motions, while in real life biters often rip or tear skin and sometimes bite body parts clear off the victim.

Dr. Bush described the process used to photograph the indentations left in the cadaver skin by the pinching device. After the cadaver was pinched, she would immediately climb up onto a ladder and take a picture. This had to be done quickly, as the indents faded within a few minutes, leaving nothing behind. She agreed that distortions created by the pinching device would be present in the photographs. She did not record the time lag between pinching and picture-taking, nor did she take photos at different time intervals to record how differently the pinch marks would appear over time. She conceded that the short interval between pinching and photography was another significant difference from a real world situation. In the real world, photos of wounds are not taken for hours or days after infliction, not within minutes. And, instead of disappearing within minutes, bitemarks last for days or weeks, changing appearance over time and sometimes leaving permanent scars.

Dr. Bush maintained that none of these differences between the real world and her model detracted from the validity of her experiments. Instead, she defended her choice of cadavers and the vice grip pinching device, saying that by controlling all the “variables” present in a living victim of a real world bitemark, and by ignoring the bruising, bleeding, abrasions, contusions, dragmarks and other features that forensic odontologists rely on when analyzing and comparing bitemarks to suspected biters, she could better focus on the indentations left by the vice-grip device. This was so, she maintained, even though those indentations would not be visible to, or used by, a forensic odontologist in a real world bitemark case.

Dr. Bush acknowledged that in her publications describing these experiments, she used the following phrases: “The authors understand that the use of cadaver skin may not replicate living

tissue,” “It is acknowledged that cadaver skin differs from living tissue, with its lack of inflammatory response and potential subcutaneous bleeding;” “The authors understand that the use of cadaver skin may not replicate living tissue, and the distortional capabilities may be different in vital versus non-vital tissue;” and “It is acknowledged that experiments occurred on cadaver skin and that results may differ on live tissue.”

The second set of experiments Dr. Bush conducted were an attempt to determine whether each person’s dentition is unique. While it is impossible to compare the teeth of every person in the world, or every person who has ever lived, Dr. Bush attempted to design an experiment that would prove or disprove uniqueness. Her experiment involved scanning tooth models provided by a company that makes dental appliances and then applying a statistical process called Procrustes analysis. Procrustes analysis, or “one size fits all” was named for a mythical Greek figure, who invited travelers to sleep in his magical bed which he promised would fit all comers. In fact, if travelers were too tall for the bed, Procrustes would chop off their legs; if they were too short, he would stretch them to fit. In either case, he won, because when they died as a result of his ministrations, he would take all their stuff.

Procrustes analysis was developed to measure large numbers of samples in aid in biological research. It was used, for example, to analyze fish scales to determine whether fish were of the same species. In Procrustes analysis, in order to compare the shapes of various things, the sizes of those things are “normalized” or made uniform, even though they might be vastly different in real life. For example, a dime, a dinner plate and the planet Earth would be “normalized” and would be deemed to be the same under Procrustes analysis.

Dr. Bush “normalized” the scanned models, making the teeth and the arches all the same size, regardless of their actual dimensions. Then, she placed dots called landmarks on each item. In

Dr. Bush's experiment, the width of the teeth were disregarded and landmarks were placed only along the length, because, as Dr. Bush testified, it was "hard" to see the tooth width in the scans. Using only the middle six teeth per dentition, Dr. Bush applied between two and three landmarks on each tooth, creating a series of straight lines rather than the outline of the tooth. She then performed a Procrustes analysis, which meant that those landmarks, or data points, are compared by computer. The goal was to see how many sets of teeth were "the same", that is, within a certain "Procrustes distance" from each other. Those parameters were set by Dr. Bush. The farther the "Procrustes distance" the more dissimilar two items would be. The closer the "Procrustes distance" was, the more alike those items would be. Despite the fact that two of the exact same dentitions were scanned, landmarked and examined, Dr. Bush determined that none of the sets of teeth were exactly the same, including the identical set. Two sets of teeth were deemed to be very similar or "the same", based on the positions of the landmarks she applied. Dr. Bush testified that with regards to the two dentitions she deemed to be very similar or "the same", she never examined either of the stone models from which the scans were made, in order to see what differences might be apparent to the naked eye. Instead, her analysis relied entirely on the 2 or 3 landmarks she applied, which disregarded the majority of the information presented by the models. Her methods were vastly different from what a forensic odontologist would do in a real life case, that is, to make a feature by feature visual examination of two items offered for comparison. And, according to testimony by Dr. Karen Kafadar, an expert in applied statistics called by the defense, Dr. Bush's procedures also violate protocols used generally in pattern impression analysis. According to Dr. Kafadar, in real world cases, after computers sort data, humans must make a visual comparison of actual specimens to render an opinion. Dr. Kafadar testified that this is true in pattern impression evidence analysis in fields like fingerprint comparisons, ballistics, handwriting comparisons in questioned document cases, and bitemark analysis and comparison. She noted whatever data is not

collected is then ignored. Dr. Kafadar testified that a flawed experimental model is likely to produce flawed results and that no statistical analysis will rescue a poorly designed experiment.

These “scanned dentition” studies failed to disprove that dentitions are unique, despite the conclusions claimed by Dr. Bush. In fact, based on Dr. Bush’s conclusions that no two sets of dentitions were exactly the same, with a zero degree of difference, she in fact proved that the dentitions she examined were unique.

Notwithstanding the obvious flaws in her experimental models, and her acknowledgment that her work was preliminary at best, and has never been replicated or validated by other researchers, Dr. Bush maintained that her experiments support the proposition that forensic odontology lacks scientific rigor and could not aid the finders of fact in a criminal or civil case. Her reluctance to recognize that her experimental models are not analogous to real life demonstrates her distance from the actual practice of forensic dentistry. (A detailed criticism of the Bush cadaver experiments in the form of a Letter to the Editor of the Journal of Forensic Sciences by a distinguished panel of board certified forensic odontologists is attached in the Appendix. A detailed criticism of the Bush scanned dentition uniqueness studies, in the form of a second Letter to the Editor of the Journal of Forensic Sciences by a similarly distinguished panel of board certified forensic odontologists is also attached.)

Applicable Legal Standard

In determining the admissibility of expert witness testimony New York state courts follow the standard established in Frye v. United States, 293 F. 1013, 1014 (D.C. Cir. 1923); see also People v. Middleton, 54 N.Y.2d 42, 49 (1981); People v. Wesley, 83 N.Y. 2d 417, 423 (1994). Frye requires that testimony of an expert witness concerning a new or novel scientific theory be established as reliable or generally accepted by the relevant scientific community. People v. Wernick, 89 N.Y.2d 111

(2001). Frye “emphasizes counting scientists’ votes, rather than verifying the soundness of a scientific conclusion.” People v. Wesley, 83 N.Y. 2d 417, 439 (1994). A particular procedure need not be “unanimously endorsed” by the relevant scientific community, however the science or technology must be “generally accepted” as reliable. People v. Middleton, 54 N.Y.2d (holding that identification through bite marks is accepted within the scientific community). When a party is granted a Frye hearing to challenge the admissibility of generally accepted expert testimony they bear the burden of demonstrating that the method is no longer accorded general scientific acceptance. Here, the defense has failed to show that the methods commonly used in forensic odontology are unreliable or are no longer generally accepted.

The make-up of the relevant scientific community is and should be those who have the knowledge, training and experience in bitemark analysis and who have actually done real world cases. We enter a looking-glass world when the defense urges that the Court ignore the opinions of working men and women who make up the ranks of board-certified forensic odontologists, who respond to emergency rooms and morgues, who retrieve, preserve, analyze and compare evidence, who make the reports and who stand by their reasoned opinions under oath. The defense would instead have this Court rely on the opinions of statisticians, law professors and other academics who do not and could not do the work in question. When Dr. Kafadar and her NAS committee created the NAS report, they wrote a summary assessment of forensic odontology. In it they said that “the majority of forensic odontologists are satisfied that bite marks can demonstrate sufficient detail or positive identification...” She agreed in her testimony that statement did, indeed, reflect the majority opinion among the scientific community of forensic odontologists. Drs. Senn, Bush and Kafadar all agree that dentists are, by virtue of training and experience, uncommonly good at pattern recognition, thorough their long years of examining dental x-rays and comparing them with prior images for signs of change. In addition, by virtue of their experience making incisions in skin and

monitoring the skin's healing, dentists spend lots of time focused on the reaction of skin to injury. Common sense and experience tell us that dentists are well-positioned to acquire the skills necessary to perform the tasks integral to forensic dentistry.

And while it is some relief to know that Drs. Michael West and Michael Bowers no longer plan to testify in bitemark cases, that reluctance could be traced to something other than a sudden epiphany about forensic dentistry. Neither is still certified by the ABFO, having resigned under fire. Dr. Bowers admitted publicly and under oath that he deliberately manipulated the evidence in a criminal case in Alabama. Dr. West has been publicly proven wrong by Dr. Senn and other forensic dentists in several high-profile cases, notably for mistaking crawfish bites for human bites and for attributing those bites to people later exonerated by DNA .

Admissibility of Bitemark Testimony in New York

In People v. Middleton, 54 N.Y.2d 42 (1981) the New York Court of Appeals held that the reliability of the bite mark evidence as a means of identification was sufficiently established in the scientific community to be admissible as evidence in a criminal case. The Court of Appeals found that techniques such as photography, freezing of tissue samples, taking of dental molds and visual observation were generally accepted and approved by the majority of experts in the field of forensic odontology. Middleton, 54 N.Y.2d at 53. The Court of Appeals further noted that since these techniques were “accepted as reliable by all of the appellate courts having been presented with bite mark comparison evidence it was unnecessary to subject these well-established methodologies to a Frye hearing in New York.” Middleton, at 49-50

Again in People v. Smith, 63 N.Y.2d 41, (1984) the New York Court of Appeals affirmed the reliability of bite mark comparison evidence, holding that photographs of bite marks on different victims compared with a stone dentition of the suspected biter's teeth is an accepted technique in

the field of forensic odontology. In Smith, forensic odontologists used two methods not addressed in Middleton. First, the forensic odontologists compared a stone dentition of the defendant's teeth, and a wax impression made therefrom, with a photograph of the bite mark on the deceased victim's breast. Second, the expert compared a photograph of the bite mark on the victim's breast with a photograph of a bite mark wound created by the defendant on the nose of another victim four years earlier. As Dr. Bush did at this hearing, the defense expert in Smith argued that the "skin is not a good medium for registering bite marks", noting distortion caused by "differences in the elasticity of skin and in skin properties depending on the affected area of the body." (Id. at 62). The Court of Appeals was not persuaded by defense expert's argument and held that no error had been made by the trial court in admitting the photo-to-photo comparison of the bite marks as evidence.

In People v. Bethune 105 A.D.2d 262 (2nd Dept. 1984) the Appellate Division reaffirmed the Court of Appeals' holdings in Middleton and Smith. The court expressly stated that "in New York, it is recognized that bite mark evidence, i.e. the comparison of impressions made upon a person's body with the dentition of another, has gained general acceptance in the scientific community as a reliable means of identification, and such evidence is therefore admissible in a criminal case." As in Middleton and Smith, the forensic odontologists in Bethune compared models made from the victim's teeth and corresponding aluwax impressions with photographs of the bite mark scar on the defendant's arm.

Exonerations

Although expert testimony in the field of forensic odontology has been admissible in New York since 1981, forensic odontology, like all areas of science, is subject to human error. Accuracy and reliability of bite mark comparison and identification relies heavily on the experience and

training of each individual expert. It is the individual experts, not the methodologies in the field of forensic odontology, who have caused the wrongful convictions noted in the defense's brief.

Forensic dentists can make mistakes, as can surgeons and airline pilots, submariners and subway conductors. The fact that all human endeavors are subject to error is not a reason to stop them.

Each wrongful conviction represents a failure of the criminal justice system and a personal tragedy for the individuals involved. However, mistakes by unskilled, untutored or unscrupulous forensic dentists do not implicate every forensic dentist or forensic odontology as a whole.

Two New York cases listed by the defense illustrate some common issues. In 1992, Roy Brown was convicted in upstate Cayuga County for the murder of a social worker who had threatened to remove his children from his custody. Evidence presented by the prosecution included prior threats the defendant made against the victim, the defendant's admission to killing a girl and that he "would often bite people when angry." People v. Brown, 82 N.Y.2d at 555. A forensic odontologist called to examine the seven bite marks found on the victim's body concluded that the defendant's dental impressions and bite marks on the body shared an identical bite patterns, including the same location of three missing teeth. In 1993, the Appellate Division, Fourth Department confirmed Roy Brown's conviction. Later, the Court of Appeals denied the defendant's appeal. Subsequent DNA testing revealed that O'Donnell was not the perpetrator.

In 1998, James O'Donnell was convicted of attempted sodomy and second degree assault of a Staten Island woman. The victim identified the defendant as her attacker in both a photo array and a live line-up. A second eyewitness confirmed the victim's identification of the defendant as the attacker. When questioned about his whereabouts on the morning the victim was sexually assaulted, the defendant provided police with an alibi that police later determined was false. In addition to this

evidence, a forensic odontologist identified the bite mark left on the victim's hand as consistent with the defendant's teeth. DNA testing later revealed that O'Donnell was not the perpetrator.

Yet another case, this one from Ohio, involved Douglas Prade, a former police officer who in 1998 was convicted of killing his estranged wife. He refused to sign the final divorce decree that would have removed him as beneficiary of her life insurance, and he knew through listening to her phone calls that she was about to announce her engagement to another man. Evidence besides a bitemark through clothing on the victim's arm consisted of hundreds of hours of wiretaps Prade illegally made of his wife's phone calls, calculations in his own handwriting listing his outstanding debts and how much money he would have left over after using his dead wife's insurance proceeds to pay them off as well as a false alibi he asked a friend to provide. Post-conviction testing on the victim's lab coat which she wore on her hospital rounds revealed an unknown DNA profile, and formed the basis for the recent vacatur of the conviction. Dr. Bush testified in that post-conviction hearing regarding her cadaver and uniqueness studies in an attempt to discredit bitemark testimony. In her decision, Judge Judy Hunter described Dr. Bush's testimony and said she found "...the premises and methodologies problematic..." Prosecutors are appealing the reversal; the defendant's convictions for the illegal wiretaps stand.

In neither Brown , O'Donnell nor Prade was bitemark testimony the sole piece of evidence presented against the defendant. To discredit the entire field of forensic odontology in response would require disregarding the other testimonial and physical evidence of the defendant's guilt presented by the prosecution.

On its websites and in many presentations and publications, The Innocence Project describes the causes of wrongful convictions. The Innocence Project blames faulty eyewitness accounts for most wrongful convictions. The solution by the criminal justice system has been to

strengthen eyewitness testimony by putting new lineup and photo array procedures in place. The Innocence Project likewise blames “false confessions” for many wrongful convictions. The solution by the criminal justice system has been to strengthen confidence in confession evidence by videotaping statements. In neither situation have the courts considered wholesale preclusion of the “offending” testimony.

The same techniques described by Dr. Senn, such as photography, freezing of tissue samples, taking of dental molds and visual observation have satisfied the Frye standard for admissibility since the Court of Appeals decision in Middleton in 1981. Those same techniques are recognized, approved and prescribed by the American Board of Forensic Odontology. There is no evidence that contradicts the efficacy of these methods. The testimony of forensic dentists should be admissible at trial to assist the jury in evaluating the bite mark evidence in criminal and civil cases.

The Importance of Forensic Odontology

There is no greater measure of the importance that forensic odontology plays in the criminal justice system than the priority the Innocence Project places on obtaining the advice of board-certified forensic dentists when the freedom of their own clients is at stake. They obviously set great store by the testimony of Dr. Senn and his colleagues. When challenging the bitemark evidence in the cases of Bennie Starks and Robert Lee Stimson and Kennedy Brewer and Levon Brooks, the Innocence Project got Dr. Senn and a team of other forensic dentists to review the evidence. The Innocence Project was pleased with the results of their analysis and comparison of the bitemark evidence and submitted those results to the court. And when the Innocence Project itself was under fire, when they were sued by the medical examiner in another bitemark case, it was again Dr. Senn whom they asked to analyze bitemark evidence and again his report they relied on in their defense.

This past February, after making a presentation to the Forensic Odontology Section of the American Academy of Forensic Sciences about a client named William Richards, the California Innocence Project asked current ABFO president Greg Golden for help finding forensic dentists to review Mr. Richard's case, which involves bitemarks. Were the Court to preclude this important category of evidence, many innocent lives could be ruined.

It is important to remember how valuable the testimony of forensic dentists is in cases where the finder of fact, be it judge or jury, needs help to interpret this complicated evidence. Dr. Senn testified about a recent case where he examined bitemarks on a toddler who spent time with her mother, the mother's live-in boyfriend, a babysitter and the babysitter's child. The mother's boyfriend was the immediate suspect and was ordered by a judge to stay away from home while the investigation was pending. Dr. Senn identified the bitemarks as having been inflicted by the babysitter's child, lifting a cloud of suspicion from the innocent boyfriend. In another child abuse case, reported by Dr. Robert Shapiro, director of the Mayerson Center for Safe and Healthy Children at Cincinnati Children's Hospital in Ohio, a baby girl came in with what the pediatric ER physicians thought were bites inflicted by a child. The forensic dentist who examined the baby identified the mother as the source of the bites, and the mother confessed to the abuse. The child was removed from her custody and saved from further harm.

Conclusion


Forensic odontology, involving every phase of the process, from collection of pattern injuries suspected to be bitemarks, to analysis of that pattern injury, to comparison of bitemarks to suspected biters and the linkage conclusions made therefrom, has been and continues to be reliable and generally accepted within the relevant scientific community. The testimony of Dr. Senn as well as the detailed direction given by the American Board of Forensic Odontology regarding every

phase of forensic dentistry proves that forensic dentistry meets the Frye standard, and should remain admissible in court.

Respectfully submitted,
May 16, 2013
New York, New York

MELISSA MOURGES

BY:

A handwritten signature in cursive script, appearing to read "Melissa Mourges", is written over a horizontal line.

MELISSA MOURGES

Assistant District Attorney

New York County District Attorney's Office

One Hogan Place, New York, NY 10013

(212) 335-4209

ELIZABETH D'ANTONIO

New York Law School Student Intern

AMANDA HERSH

Fordham Law School Student Intern

SUPREME COURT OF THE STATE OF NEW YORK
COUNTY OF NEW YORK

THE PEOPLE OF THE STATE OF NEW YORK

-against-

CLARENCE DEAN,

Defendant.

REPLY TO POST-FRYE HEARING BRIEF REGARDING FORENSIC
ODONTOLOGY

IND. NO. 4555/2007

Cyrus R. Vance, Jr.
District Attorney
New York County
One Hogan Place
New York, New York 10013
(212) 335-9000

Melissa Mourges
Assistant District Attorney
Of Counsel